

## Original Research Article

# Enveloped double purse-string versus conventional pancreaticogastrostomy during Whipple procedure: comparative study at Sohag university onco-surgery program

Ashraf M. El-Badry<sup>1\*</sup>, Alaa A. Redwan<sup>1</sup>, Mohammad A. Abusedera<sup>2</sup>, Hitham M. Ali<sup>3</sup>

<sup>1</sup>Department of General Surgery, <sup>2</sup>Department of Radiology, <sup>3</sup>Departemnt of Anesthesia and Intensive care, Sohag University Hospital, Faculty of Medicine, Sohag University, Sohag, Egypt

**Received:** 02 November 2016

**Accepted:** 07 November 2016

### \*Correspondence:

Dr. Ashraf Mohammad El-Badry,

E-mail: [ashraf.elbadry@med.sohag.edu.eg](mailto:ashraf.elbadry@med.sohag.edu.eg)

**Copyright:** © the author(s), publisher and licensee Medip Academy. This is an open-access article distributed under the terms of the Creative Commons Attribution Non-Commercial License, which permits unrestricted non-commercial use, distribution, and reproduction in any medium, provided the original work is properly cited.

### ABSTRACT

**Background:** Pancreatico-gastrostomy (PG) is widely applied for restoration of connection between the distal pancreatic remnant and digestive tract during Whipple procedure. Comparative studies on the clinical outcome of various PG techniques are scarce.

**Methods:** Medical records of patients who underwent PG at Sohag University Hospital (November 2012-December 2015) were reviewed. Patients who had PG using our new technique of enveloped double purse-string sutures (EDPS-PG) were compared with control group of conventional transfixing suture PG regarding the postoperative outcome.

**Results:** Twenty-seven patients (18 conventional PG and 9 EDPS-PG) were enrolled. Grade C postoperative pancreatic fistula (POPF) occurred only in the conventional PG group. Patients in the EDPS-PG group needed significantly shorter time before removal of the abdominal drains ( $p = 0.04$ ), significantly reduced length of hospital stay ( $p = 0.03$ ) and significantly lower grades of postoperative complications ( $p = 0.02$ ) compared with the conventional PG group. Postoperative death occurred only in one patient in the control group. No significant difference could be found regarding operative time, postoperative bleeding delayed gastric emptying or bile leak.

**Conclusions:** EDPS-PG is new, simple and safe technique for PG during Whipple procedure and results in significant reduction of POPF and overall complications.

**Keywords:** Pancreatico-gastrostomy, Pancreaticotomy, Whipple

### INTRODUCTION

Restoration of the connection between the pancreatic remnant and the digestive tract during whipple procedure (pancreatico-duodenectomy (PD)) remains as source of concern.<sup>1</sup> Anastomotic failure is associated with increased risk of postoperative complications, among which POPF is particularly troublesome.<sup>2</sup>

Traditionally, pancreatico-enteric anastomosis was carried out by pancreatico-jejunostomy (PJ). However,

PG is theoretically less demanding and has lesser liability to ischemia and more protection to the anastomosis due to the acidic nature of the gastric secretion which prevents activation of the pancreatic enzymes.<sup>3</sup> The anatomical location of the stomach nearby the pancreatic remnant enables tension-free anastomosis.<sup>4</sup> Tailoring the extent of posterior gastrostomy incision according to that of the pancreatic stump facilitates sufficient invagination of the pancreatic remnant inside the stomach and eliminates the problem of discrepancy between the size of the pancreatic remnant and the jejunal circumference that

might exist with pancreatico-jejunostomy.<sup>5</sup> Moreover, performing two anastomoses in single jejunal loop when PG is applied instead of three in pancreatico-jejunostomy is likely to abolish the opportunity of jejunal kink.<sup>5</sup>

PG was introduced clinically by Waugh and Clagett in and evolved through several modifications.<sup>6-12</sup> Clinical studies during the nineties and almost the first decade of the current century showed that the incidence of postoperative complications, including POPF, after application of PJ versus PG were not significantly different.<sup>13-15</sup> However, more recent data provide clear evidence that PG is superior to PJ in terms of reduction of postoperative complication rates, principally the incidence of POPF.<sup>16-23</sup>

In this study, we describe new EDPS technique for PG during Whipple procedure. Our approach entails insertion of the pancreatic remnant into the interior of the stomach via posterior gastrostomy. The telescoped pancreatic stump is encircled by two purse-string sutures which are tied in opposite directions at 180 degrees angle. The purse-string sutures are enveloped inside two layers of transfixing sutures.

Furthermore, we evaluated the influence of EDPS-PG on the postoperative clinical outcome regarding postoperative morbidity, including POPF, and mortality compared with conventional PG.

## METHODS

Medical records of patients who underwent PG at Sohag University Hospital (November 2012-December 2015) were retrospectively reviewed. Patients who underwent EDPS-PG were compared with conventional PG control group. PG was carried out electively during PD for adenocarcinoma of the pancreatic head, ampulla of Vater and the distal common bile duct. All operative interventions were performed in adult patients by the same surgical team. The technique of EDPS-PG was developed by Dr. Ashraf M. El-Badry (the first author).

Exclusion criteria comprised liver metastasis, borderline resectable pancreas cancer defined according to Katz et al as abutment of visceral arteries by the pancreatic neoplasm or occlusion of a short segment of the superior mesenteric vein were excluded vascular resections and preoperative chemotherapy.<sup>24</sup>

Preoperative imaging entailed abdominal ultrasonography; contrast enhanced computed tomography (CT) of the abdomen and chest. The CT protocol comprised thin section CT scan during pre-contrast, arterial and portal phases for precise assessment of the extensions of the tumor, vascular encasement, and biliary obstruction and to exclude metastasis particularly to the liver or regional lymph nodes. Preoperative endoscopic retrograde cholangio-pancreatography was carried out in selected patients who were referred from

gastrointestinal endoscopy units after stenting of the common bile duct for relief of obstructive jaundice. Tumor marker studies entailed assessment of blood levels of carbohydrate antigen 19:9 and carcinoembryonic antigen. Classic Whipple procedure was performed in 24 patients and pylorus preserving PD in 2 patients as previously described.<sup>25,26</sup>

PG was the method of restitution of the connection between the pancreatic remnant and the gastro-intestinal tract in all patients. In the control group, the pancreatic stump was fixed to the edges of posterior gastrostomy by 3/0 interrupted silk sutures. Telescoping the pancreatic stump was aided by traction via another anterior gastrostomy.

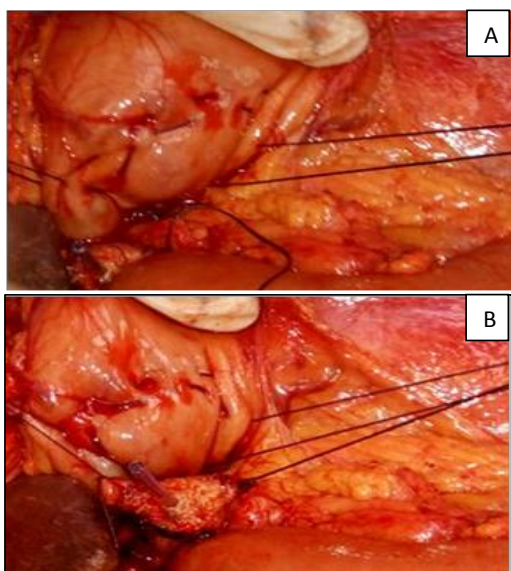
In the EDPS-PG group, an outer seromuscular purse-string 3/0 PDS suture opposite to and one cm larger than the pancreatic stump diameter is initiated at 3 o'clock position in the posterior gastric wall. The outer seromuscular purse-string suture is placed one cm cranial to posterior transfixing 3/0 suture which is applied to sew up the posterior gastric wall and the capsule of the posterior surface of the pancreas 2 cm distal to the pancreatic stump. Inner seromuscular purse-string 3/0 suture commenced at 9 o'clock position is set one cm inside the outer suture (Figure 1A).

Posterior gastrostomy is made along the entire diameter of the inner purse-string ring by full-thickness incision of the posterior gastric wall. Plastic stent is inserted inside the pancreatic duct to avoid pancreatic duct obstruction (Figure 1B).

The width of posterior gastrostomy should eventually be slightly smaller than the diameter of the opposite segment of the pancreatic remnant. The distal 2 cm segment of the pancreatic remnant is held by single 2/0 silk suture with straight needle. The needle is passed via the posterior gastrostomy into the anterior gastric wall, held outside the stomach and gently pulled to aid telescoping of the pancreatic remnant into the interior of the stomach.

The inner and outer purse-string sutures are respectively tied followed by withdrawal of the 2/0 silk suture. Anterior seromuscular transfixing 3/0 silk suture is run between the posterior gastric wall and the capsule of the anterior surface of the pancreas.

Two drains are positioned nearby the PG and the hepaticojejunostomy. The effluent is daily checked for the amount and color. Based on the definition of International study group for pancreatic fistula, the amylase levels in the effluent fluid and serum are measured on postoperative days three, five and seven.<sup>27</sup> Drains are removed if no fistula is confirmed. Delayed gastric emptying (DGE) was defined according to the International study group of pancreatic surgery.<sup>28</sup>



**Figure 1: (a) Double purse string sutures placed in the posterior gastric wall; (b) Posterior transfixing suture line (gastric seromuscular layer and the posterior pancreatic capsule). Stent placed inside the pancreatic duct.**

The severity of postoperative complications was ranked according to Clavien-Dindo classification.<sup>29</sup> For each patient, an overall score of postoperative complications

(ranging from one to seven) was concluded via assigning one point to each of grades I, II, IIIa, IIIb, IVa, IVb and V in a ascending order. Statistical analysis was carried out by GraphPad Prism 6.0 software.

## RESULTS

Twenty seven patients were enrolled, 18 in the control group of conventional PG and 9 in the EDPS-PG. The median age was 61 (range: 42-68) years in the control group and 65 (range: 34-71) years in the EDPS-PG group. There were eleven males in the control group (61%) and 6 (67%) in the EDPS-PG group.

The relevant clinical, laboratory and imaging data as well as the indications for surgery were not significantly different between both groups (Table 1).

Likewise, the operative time, texture of the pancreatic remnant, pancreatic duct size, blood loss, blood transfusion and types of pancreatic resection did not differ significantly in both groups. A summary of operative data is shown in (Table 2).

Grade A POPF developed in one patient in each group and required no intervention. Grade C fistula occurred only in the control group in two patients with soft pancreatic parenchyma. The first patient underwent two re-laparotomies to revise leaking pancreatico-gastric anastomosis. In the other patient, POPF was further complicated by sepsis, multiorgan failure, pulmonary embolism and death.

**Table 1: Preoperative data.**

	Conventional PG	EDPS-PG	P-value
<b>Clinical history: number (%)</b>			
Smoking	5 (28)	2 (22)	ns
Pruritis	15 (83)	7 (78)	ns
Anorexia	16 (89)	7 (78)	ns
Abdominal pain	8 (44)	4 (44)	ns
Diabetes	3 (17)	2 (22)	ns
<b>Laboratory data: median (range)</b>			
Total bilirubin (mg/dl)	10.5 (4.8-17.3)	10.8 (6.5-14.8)	ns
Albumin (g/dl)	4.25 (3.4-5.2)	4.2 (3.7-4.9)	ns
Prothrombin time (minute)	12 (11-14)	11 (11-13)	ns
Creatinine (mg/dl)	1 (0.6-1.3)	0.9 (0.8-1.2)	ns
Hemoglobin (g/dl)	12.9 (11.3-15.1)	13.4 (12.3-14.6)	ns
<b>Imaging: median diameter (range)</b>			
Tumor (cm)	2.8 (2.3-3.7)	3 (2.6-3.6)	ns
CBD (ml)	16 (12-21)	14 (11-19)	ns
<b>Indications for surgery: number (%)</b>			
Pancreatic adenocarcinoma	11 (61%)	6 (67%)	ns
Distal cholangiocarcinoma	5 (28%)	2 (22%)	ns
Ampullary carcinoma	2 (11%)	1 (11%)	ns

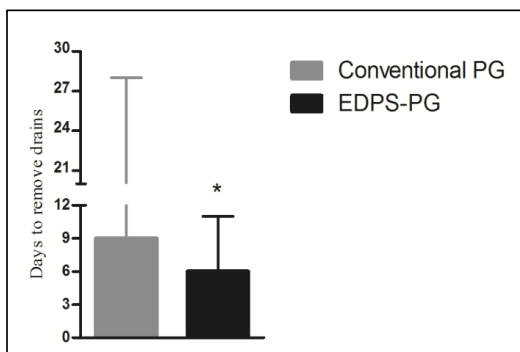
ns: non-significant

**Table 2: Operative data.**

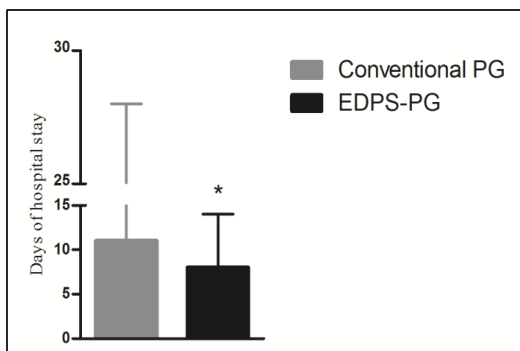
	Conventional PG	EDPS-PG	P-value
Duration of surgery (minute)	322 (241-440)	328 (216-416)	ns
<b>Pancreatic remnant consistency: number (%)</b>			
Soft	5 (28%)	3 (33%)	ns
Firm-hard	13 (72%)	6 (67%)	ns
Blood loss (ml)	445 (290-960)	410 (320-610)	ns
Blood transfusion (unit)	1 (0-3)	1 (0-2)	ns
<b>Type of surgery: number (%)</b>			
Classic PD	17 (94%)	8 (89%)	ns
Pylorus preserving PD	1 (6%)	1 (11%)	ns

ns: non-significant

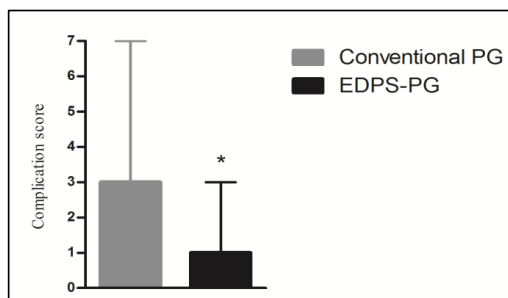
Grade A DGE developed in 3 patients in the control group and two patients in the EDPS-PG group and resolved spontaneously in all patients. Bile leak, pancreatitis and intra-abdominal hemorrhage were not encountered postoperatively in either group. Wound sepsis occurred in 2 patients per group and was successfully managed by systemic antibiotics and local debridement.



**Figure 2: Days to remove drains (\* p = 0.04).**



**Figure 3: Days of hospital stay (\* p = 0.03).**



**Figure 4: Score of postoperative complications (\* p = 0.02).**

The median duration of insertion of abdominal drains in the EDPS-PG group was 6 (range: 5-11) days which was significantly shorter in comparison with 10 (range: 7-28) days in the control group,  $p = 0.04$  (Figure 2). EDPS-PG was associated with significant reduction of the length hospital stay (median: 8; range: 6-14 days) compared with (median: 11.5; range: 9-28 days) in the conventional PG group,  $p = 0.03$  (Figure 3). In the same line, the median score of postoperative complications was 1 (range: 0-3) in the EDPS-PG which was significantly lower compared with the control group 3 (1-7),  $p = 0.02$  (Figure 4).

Only one patient died in the control group on POD 28 following the development of grade C POPF, sepsis, multiorgan failure and pulmonar embolism. There was no mortality in the EDPS-PG group.

## DISCUSSION

This study "introduces our new EDPS-PG technique during PD. We showed that this new technique results in significant reduction in POPF and amelioration of postoperative complications compared with conventional PG.

Delcore and his co-workers described telescoping the pancreatic remnant into the interior of the stomach through posterior gastrostomy. Insertion of the remnant pancreas was assisted by pulling the pancreatic stump via a second gastrostomy in the anterior wall of the stomach. The pancreatic stump was then fixed to the stomach by two layers of sutures transfixing the pancreatic remnant to the exterior and interior of the posterior gastric wall.<sup>30</sup> A binding PG can be carried out by tying two already placed purse-string sutures internally in the gastric mucosa and externally in the seromuscular layer around the posterior gastrostomy and the telescoped pancreas.<sup>8</sup> Alternatively, Narita et al strapped the telescoped pancreatic remnant by two external purse-string sutures around the posterior gastrostomy.<sup>11</sup> These technique may be limited by the addition of another anterior gastrostomy and possibly prolongation of the operative time.<sup>8,11,30</sup> Another group described pulling the pancreatic stump via the open gastric stump to avoid the addition of anterior gastrostomy. The telescoped pancreatic remnant is fixed by tying two external seromuscular purse-string sutures in the 9 o'clock position around the posterior gastrostomy.<sup>10</sup>

Despite the wide range of PG techniques, none has combined the use of purse-string and transfixing sutures to ensure better fixation of the telescoped pancreas. Moreover, the current literature contains no comparative studies on the outcome of various PG procedures.

In this study, both conventional and EDPS PG groups were comparable regarding the presenting symptoms such as anorexia, pruritis and abdominal pain, pertinent laboratory parameters such as preoperative levels of bilirubin, albumin, creatinine and hemoglobin. Preoperative coagulation profile was normal in both groups. Indications for PD were almost similar in both groups. The diameter of the tumor and the consequent dilataion of the common bile duct did not differ significantly between boh groups. Intra-operatively, the number of patients with soft pancreatic parenchyma was not significantly different between both groups. Standard PD was performed in the vast majority of patients in both groups. Application of EDPS-PG was not associated with prolongation of the operative time. Similarly, the amount of blood loss and number of units which were used for replacement were not significantly different.

Grade C POPF was not encountered in EDPS-PD patients. However, two patients who underwent conventional PD developed grade C POPF with subsequent death in one patient.

Application of our technique ensures adequate inclusion of the pancreatic stump in a sleeve of posterior gastric wall comprising two PS sutures which are further sandwiched inside double layer of transfixing sutures. This was accomplished without the need for a second gastrostomy in the anterior gastric wall as previously described.<sup>8,11,30</sup> We could not document that avoidance of

anterior gastrostomy has significantly reduced the operative time, however elimination of unnecessary gastrostomy is indeed more phyysiologic. In comparison with Addeo a et al who placed the ties of double external PS sutures only in the 9 o'clock position, our strategy of tying the PS sutures in opposite direction of 180 degrees angle (3 and 9 o'clock positions) provides further support of the pancreatic stump inside the gastric sleeve.<sup>10</sup> This is particularly substantial for securing the PG in case of soft pancreatic parenchyma. Furthermore, the addition of anterior and posterior rows of transfixing sutures provides strong envelop around the PS sutures to further stabilize the pancreatico-gastric anastomosis.

The study is limited by the inherent defects of the retrospective methodology and the relatively small number of patients in the EDPS-PG group. However, the obvious similarity between both groups regarding the preoperative demographic, clinical; laboratory and imaging data, the operative findings, and the clear difference in the postoperative complications would strongly support our conclusions.

## CONCLUSION

We propose that our new EDPS-PG technique provides remarkable strength to the PG secures better opportunity for healing and substantially reduces the chance for anastomotic leak and postoperative complications compared with the conventional procedure of PG.

## ACKNOWLEDGEMENTS

The authors would like grateful to Dr. Abdel-Rahman Galal and Dr. Ahmed Raafat, assistant lecturers of general surgery and Dr. Ahmed Aly, assistant lecturer of anesthesiology and intensive care, faculty of medicine, Sohag university for their help and support.

*Funding: No funding sources*

*Conflict of interest: None declared*

*Ethical approval: Not required*

## REFERENCES

1. Guerrini GP, Soliani P, D'Amico G, Di Benedetto F, Negri M, Piccoli M, et al. Pancreatico jejunostomy versus pancreatico gastrostomy after pancreatico duodenectomy: an up-to-date meta-analysis. J Invest Surg. 2016;29(3):175-84.
2. Takahashi S, Gotohda N, Kato Y, Konishi M. Measure of pancreas transection and postoperative pancreatic fistula. J Surg Res. 2016;202:276-83.
3. Qin H, Luo L, Zhu Z, Huang J. Pancreatic gastrostomy has advantages over pancreaticojejunostomy on pancreatic fistula after pancreaticoduodenectomy. A meta-analysis of randomized controlled trials. Int J Surg Lond Engl. 2016;36:18-24.
4. Aranha GV. Pancreaticogastrostomy. Oper Tech. Gen Surg. 2001;3:54-60.

5. Zenilman ME. Use of pancreatic gastrostomy for pancreatic reconstruction after pancreaticoduodenectomy. *J Clin Gastroenterol.* 2000;31:11-8.
6. Telford GL, Mason GR. Pancreatic gastrostomy: clinical experience with a direct pancreatic duct to gastric mucosa anastomosis. *Am J Surg.* 1984;147:832-7.
7. Shinchii H, Takao S, Maemura K, Aikou T. A new technique for pancreatic gastrostomy for the soft pancreas: the transfixing suture method. *J Hepatobiliary Pancreat Surg.* 2006;13:212-7.
8. Peng SY, Wang JW, Hong DF, Liu YB, Wang YF. Binding pancreaticoenteric anastomosis: from binding pancreatico jejunostomy to binding pancreatico gastrostomy. *Updat Surg.* 2011;63:69-74.
9. Feng QY, Wei Y, Chen JW, Chang WJ, Ye LC, Zhu DX, et al. Anti-EGFR and anti-VEGF agents: important targeted therapies of colorectal liver metastases. *World J Gastroenterol.* 2014;20:4263-75.
10. Addeo P, Rosso E, Fuchshuber P, Oussoultzoglou E, Souche R, Nobili C, et al. Double purse-string telescoped pancreatic gastrostomy: an expedient, safe, and easy technique. *J Am Coll Surg.* 2013;216: e27-33.
11. Narita M, Matsusue R, Hata H, Yamaguchi T, Otani T, Ikai I. Double purse-string telescoped pancreatic gastrostomy using an atraumatic self-retaining ring retractor in a subtotal stomach-preserving pancreaticoduodenectomy. *Ann Surg Oncol.* 2016;23:1034.
12. Wang XA, Wu XS, Cai Y, Jin HC, Shen WM, Liu YB, et al. Single purse-string duct to mucosa pancreatic gastrostomy: a safe, easy, and useful technique after pancreaticoduodenectomy. *J Am Coll Surg.* 2015;220:e41-48.
13. Yeo CJ, Cameron MM, Maher PK, Sauter ML, Zahurak MA, Talamini KD, et al. A prospective randomized trial of pancreatic gastrostomy versus pancreatico jejunostomy after pancreaticoduodenectomy. *Ann Surg.* 1995;222: 580-588.
14. Duffas JP, Suc B, Msika S, Fourtanier G, Muscari F, Hay JM, et al. A controlled randomized multicenter trial of pancreatico gastrostomy or pancreatico jejunostomy after pancreaticoduodenectomy. *Am J Surg.* 2005;189: 720-9.
15. Fernández-Cruz L, Belli A, Acosta M, Chavarria EJ, Adelsdorfer W, López-Boado MA, et al. Which is the best technique for pancreaticoenteric reconstruction after pancreaticoduodenectomy? A critical analysis. *Surg Today.* 2011;41:761-6.
16. Chen, Z. Pancreaticogastrostomy versus pancreatico jejunostomy after pancreaticoduodenectomy: a meta-analysis of randomized control trials. *Br Assoc Surg Oncol.* 2014;40:1177-85.
17. Figueras J, Sabater L, Planellas P, Muñoz-Fornier E, Lopez-Ben S, Falgueras L, et al. Randomized clinical trial of pancreatico gastrostomy versus pancreatico jejunostomy on the rate and severity of pancreatic fistula after pancreaticoduodenectomy. *Br J Surg.* 2013;100:1597-605.
18. Lei P, Fang J, Huang Y, Zheng Z, Wei B, Wei H. Pancreatic gastrostomy or pancreatico jejunostomy? Methods of digestive continuity reconstruction after pancreaticoduodenectomy: a meta-analysis of randomized controlled trials. *Int J Surg Lond Engl.* 2014;12:1444-9.
19. Ma S, Li Q, Dai W, Pan F. Pancreatic gastrostomy versus pancreatico jejunostomy. *J Surg Res.* 2014;192:68-75.
20. Xiong JJ, Tan CL, Szatmary P, Huang W, Ke NW, Hu WM, et al. Meta-analysis of pancreatic gastrostomy versus pancreatico jejunostomy after pancreaticoduodenectomy. *Br J Surg.* 2014;101:1196-208.
21. Hallet J, Zih FS, Deobald RG, Scheer AS, Law CH, Coburn NG, et al. The impact of pancreatico jejunostomy versus pancreatico gastrostomy reconstruction on pancreatic fistula after pancreaticoduodenectomy: meta-analysis of randomized controlled trials. *HPB.* 2015;17:113-22.
22. Menahem B, Guittet L, Mulliri A, Alves A, Lubrano J. Pancreatic gastrostomy is superior to pancreatico jejunostomy for prevention of pancreatic fistula after pancreaticoduodenectomy: an updated meta-analysis of randomized controlled trials. *Ann Surg.* 2015;261:882-7.
23. Que W, Fang H, Yan B, Li J, Guo W, Zhai W, et al. pancreatic gastrostomy versus pancreatico jejunostomy after pancreaticoduodenectomy: a meta-analysis of randomized controlled trials. *Am J Surg.* 2015;209:1074-82.
24. Katz MHG, Ahmad SA, Boughey JC. Improving resection rates in borderline resectable pancreatic cancer: Pilot study shows favorable results. *Bull Am Coll Surg.* 2015;100:39-41.
25. Pisters PWT. Standard pancreaticoduodenectomy. *Oper Tech Gen Surg.* 2001;3:17-30.
26. Farnell MB. Pylorus - preserving pancreaticoduodenectomy. *Oper Tech Gen Surg.* 2001;3:31-44.
27. Bassi C, Dervenis C, Butturini G, Fingerhut A, Yeo C, Izbicki J, et al. Postoperative pancreatic fistula: an international study group (ISGPF) definition. *Surgery.* 2005;138:8-13.
28. Wente MN, Bassi C, Dervenis C, Fingerhut A, Gouma DJ, Izbicki JR, et al. Delayed gastric emptying (DGE) after pancreatic surgery: a suggested definition by the international study group of pancreatic surgery (ISGPS). *Surgery.* 2007;142: 761-8.
29. Clavien PA, Barkun J, de Oliveira ML, Vauthey JN, Dindo D, Schulick RD, et al. The Clavien-Dindo classification of surgical complications: five-year experience. *Ann Surg.* 2009;250:187-96.
30. Delcore R, Thomas JH, Pierce GE, Hermreck AS. Pancreatic gastrostomy: a safe drainage procedure after pancreaticoduodenectomy. *Surgery.* 1990;108:641-7.

**Cite this article as:** El-Badry AM, Redwan AA, Abusedera MA, Ali HM. Enveloped double purse-string versus conventional pancreatico-gastrostomy during Whipple procedure: comparative study at Sohag university onco-surgery program. *Int Surg J* 2017;4:xxx-xx.